

## Chapter 3 Breathing and Breath Support

The respiratory system—or pulmonary system—is the power source and actuator of the vocal instrument. In this capacity, the lungs serve a function similar to the bellows of a pipe organ or the air bladder of bagpipes; in essence, they function as a storage depot for air. This is not, of course, the primary biological function of the respiratory system, which must perpetually oxygenate the blood and cleanse it of excess carbon dioxide to maintain life.

### Respiratory Anatomy

The respiratory system is housed within the axial skeleton (Figure 3.1), which is the portion of the human skeleton that consists of the spine and thorax (ribcage). The remainder of the skeleton, including the skull, pelvis, arms and legs is called the appendicular skeleton. Posture is largely a function of the relative positions and balance between these skeletal regions.

#### Spine

Discussion of the respiratory framework must begin with the spine itself, which consists of twenty-four individual bones called vertebrae. Stacked together to form a gentle “S” curve in the anterior/posterior (front to back) plane, the vertebrae gradually become larger from the top to the bottom of the spinal column. The lowest five are called the lumbar vertebrae. These are the largest and thickest bones in the spine and are responsible for carrying most of the weight of the upper body. Curvature in this region acts as a shock absorber, helping to prevent injury during heavy lifting (Figure 3.2). Thoracic vertebrae make up the next twelve segments of the spine. These bones are somewhat smaller than the lumbar vertebrae and possess flat areas called facets for the attachment and articulation of the ribs.

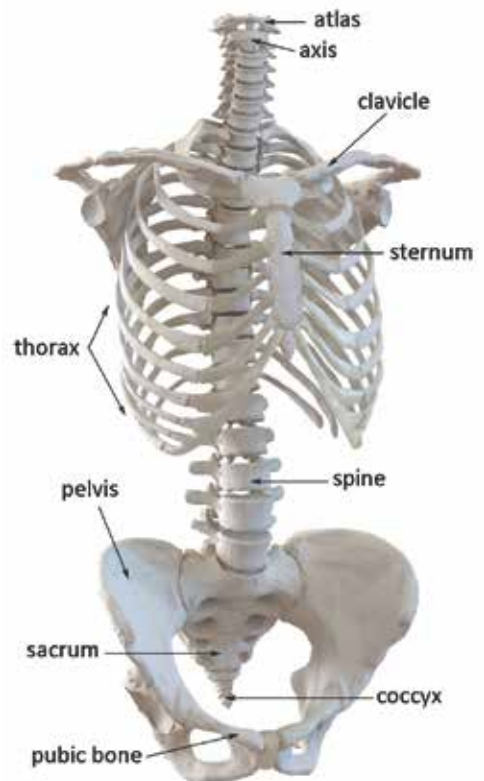


Figure 3.1: Axial Skeleton

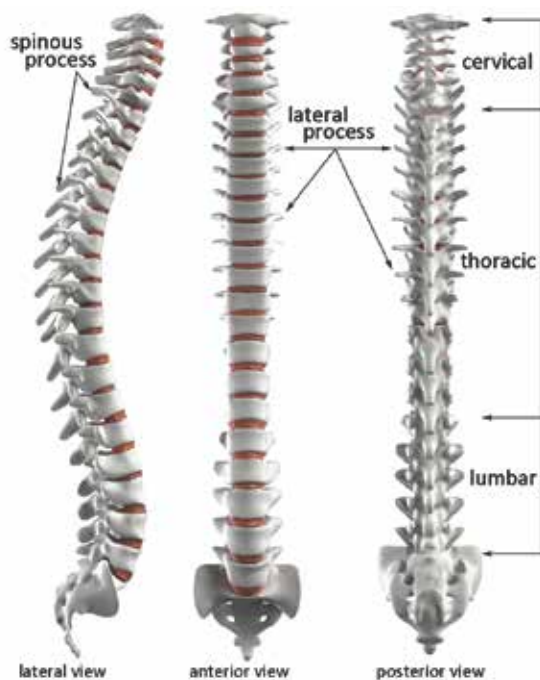

Figure 3.2: Spine

obliquely downward from the spine. The spinous process of the seventh cervical vertebrae is particularly large and can easily be seen or felt in most people, especially while bending over. This provides a landmark for the division between the cervical and thoracic regions and can be useful in establishing correct posture. Two transverse processes extend laterally from each vertebra.

At the base of the spine, five sacral vertebrae are found, which are fused together to form the sacrum. An additional five, very small vertebrae, which also are fused together, extend beyond the sacrum to form the coccyx or tailbone. The sacrum joins with a group of bones called the ilium, pubis and ischium to create the pelvis, a strong structure that serves as the attachment points for the lower extremities and as a girdle for the contents of the abdomen.

Knowledge of the structure, shape and attachments of the spine has significant pedagogic consequences. It must be remembered that the spine has a natural, s-shaped curve. While this curve should not be exaggerated, as seen in severe cases of lordosis (swayback), it should also not be removed and straightened artificially. At least one prominent text on singing technique instructs that correct posture can be established by leaning against a wall with the knees bent and the feet placed several inches forward. The singer then presses the small of his back into the wall, making it as straight as possible. Finally, he is to stand up while maintaining the same vertebral posture—and sing (McKinney, 1994). While this

The seven cervical vertebrae complete the top of the spine. The topmost cervical vertebra is called the atlas and is specially shaped to fit snugly into the base of the skull and carry the weight of the head. The second cervical vertebra, called the axis, features a projection from its anterior segment called the dens or odontoid process that inserts into the atlas. Together, these two vertebrae provide a pivot around which the skull can be tilted and rotated.

Each vertebra, except the atlas, has a small projection from its posterior called a spinous process that serves as an attachment point for muscles of the back. In the lumbar region, these projections are robust and somewhat stubby, extending nearly at a right angle to the spine. In the thoracic region, the spinous processes are longer and extend

technique might be somewhat beneficial for the correction of lordosis, the impact on normal bodies is contrived and unnatural.

When the entire skeleton is considered, another significant pedagogic implication becomes clear: the central pivot point for bending forward is located at the joint between the pelvis and the hips, not at the waist. Many singers and teachers use breathing exercises that include bending over to increase awareness of abdominal movement during respiration. If students are instructed to bend forward from the waist, the exercise compresses the abdominal area and actually inhibits free breathing. If, however, the singer bends forward from the hips while deliberately elongating the spine, space is created for the abdomen to release fully, making the exercise much more effective.

### **Thorax (ribcage)**

The thorax or ribcage houses the lungs and heart. It consists of twelve pairs of ribs that attach to the thoracic vertebrae through flexible joints that permit movement up and down (in spite of what is implied in Genesis, men and women have the same number of ribs). Limited movement also is possible in the anterior/posterior plane. The top four pairs of ribs attach individually to the breastbone or sternum through the flexible connection of the costal cartilage; ribs five through ten all share a common cartilaginous connection to the sternum (Figure 3.3). The bottom two ribs are free-floating, with no connection to the sternum and sometimes are referred to as false ribs. The sternum itself consists of two bony plates called the manubrium and the corpus. The joint between these plates is flexible at birth but fuses solid by the time we reach adulthood. At the base of the corpus, a small projection called the xiphoid process is found, to which some of the abdominal muscles attach.

The flexible connections of the ribs to the spine and sternum allow for a significant range of motion. Through contraction of respiratory muscles, the entire thorax can be raised and depressed, and made larger or smaller in circumference; all of these dimensional changes result in either inhalation or exhalation.

### **Lungs**

Why do dimensional changes of the thorax result in breathing? The answer lies in an old axiom you might remember from your school days: nature abhors a vacuum. The lungs, which lie within the thorax, are organs, not muscles, and therefore do not have the ability to

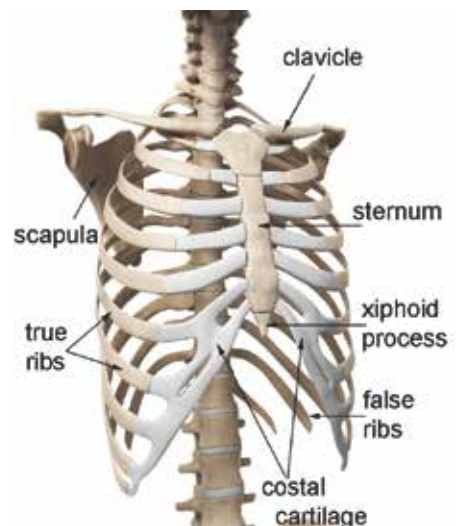


Figure 3.3: Thorax

move of their own accord. However, they still must be enlarged for inhalation and made smaller for exhalation. This can occur only because the lungs are coupled to the interior wall of the thorax by action of the pleurae, or pleural sac. The pleurae is a serous membrane (water permeable) that causes the thorax and lungs to adhere to each other with a flexible connection that has much more in common with a wet plastic bag adhering to a window than to double-sided adhesive tape. Because of the pleurae, dimensional changes in the thorax are transferred directly to the lungs; if the thorax gets bigger or smaller, the lungs do the same.

To better understand how a vacuum is created in the lungs, we must make a brief visit to the realm of physics. Robert Boyle, a 17th-century British scientist, discovered that when a gas, such as air, is contained in an enclosure, pressure and volume are inversely proportional (if one goes up, the other goes down). This is easily visualized through a syringe. When the plunger is depressed, volume in the syringe becomes smaller and pressure inside increases; conversely, when the plunger is withdrawn, volume is increased, and pressure is reduced. Because of these relationships, fluid is drawn into the syringe when the plunger is withdrawn and is ejected when it is depressed.

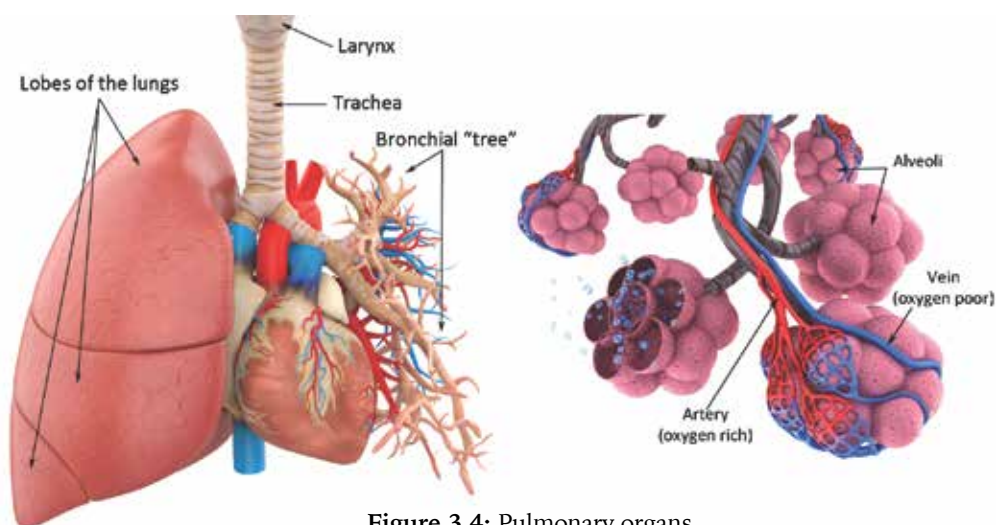


Figure 3.4: Pulmonary organs

To inhale, the volume capacity of the thorax and lungs must be increased. This, according to Boyle's Law, results in a decrease in air pressure. In fact, the air pressure in the expanded lungs becomes lower than atmospheric pressure and a vacuum is created. Air rushes in to fill this vacuum and create equilibrium between the pressures inside and outside the lungs. Exhalation reverses this process. The thorax and lungs are made smaller, decreasing their volume and thereby increasing air pressure. Air in the lungs now rushes out to equalize lung and atmospheric pressures. Because of Boyle's Law, whenever the volume capacity of the thorax and lungs is increased, inhalation occurs; whenever it is decreased,

exhalation occurs. It is extremely important to remember this cause-and-effect relationship of expansion and contraction during breathing. Expansion of the chest and/or abdomen upon inhalation causes air to rush in and fill the lungs by creating a partial vacuum; expansion is never the effect of air entering the lungs (unless the person is breathing with the mechanical support of a ventilator).

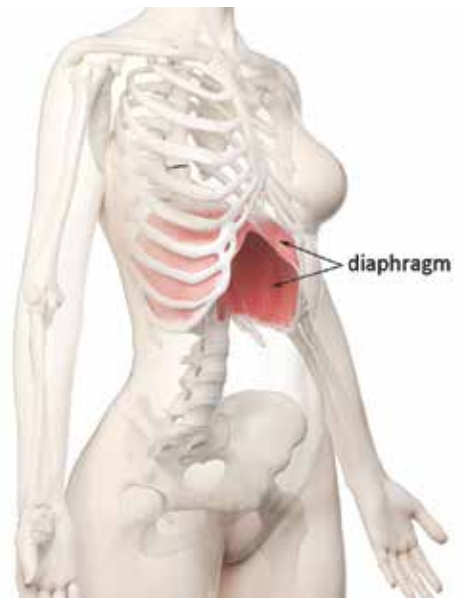
The lungs themselves are made of porous, spongy material. The right lung is composed of three separate sections, called lobes; the left lung must compete for space with the heart and therefore is slightly smaller, having only two lobes (Figure 3.4). Air comes into the lungs through the trachea (windpipe), which divides into two separate bronchial tubes. These further divide into lobar bronchi, which insert into the individual lobes of each lung. Once inside the lungs, the bronchi divide into smaller and smaller segments, eventually arriving at the alveoli or alveolar sacs, which is where the actual exchange of blood gasses occurs (Figure 3.4). The alveoli are highly compressible and are responsible for much of the elasticity of lung tissue. Healthy, mature lungs contain vast numbers of individual alveoli—about 300 million per lung (Kent, 1997). If we could remove and spread them out, they would cover the surface of a tennis court!

### **Inspiratory muscles**

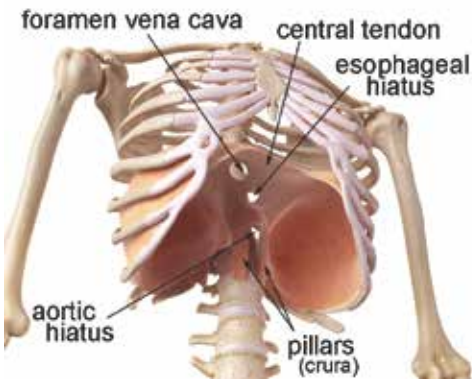
We now know that the thorax must be made larger to induce inhalation. We also know that muscles are capable of only one motion: contraction. How is it then that something is made larger through contracting—isn't this a paradoxical contradiction?

The most important muscle of inhalation is the diaphragm. This is the second largest muscle (measured by mass) in the human body—in most people, only the gluteus maximus muscles are larger. Shaped like a dome or an old-fashioned, round parachute with two small humps, the diaphragm bisects the body, separating the contents of the thorax from the abdomen (Figure 3.5). In this location, it serves as the floor to the thorax. With help from the pleurae, motion of the diaphragm is transferred directly to the lungs. On contraction, the diaphragm lowers and becomes somewhat flatter, increasing the volume capacity of the thorax and lungs, an effect similar to withdrawing the plunger of a syringe.

Many people have misconceptions about the location and size of the diaphragm. Because it is located deep within the thoracic/abdominal cavity and cannot be touched or felt externally, it often is



**Figure 3.5:** Diaphragm



**Figure 3.6:** Inferior view of diaphragm (from below)

believed to be smaller in diameter and lower in placement than is correct. Often these misconceptions arise from the best intentions of voice teachers or choir directors who teach breathing by placing a hand on the belly and telling students to “breathe from their diaphragm.” Recipients of this instruction naturally assume the outward movement of the abdominal wall is the actual diaphragm. Even well-educated singers often believe the diaphragm lies lower in and descends farther into the torso than it actually does. In reality, the diaphragm extends upward in a gentle dome from its attachment point at the bottom of the sternum; the stomach and liver lie directly below, covered by the diaphragmatic dome like an inverted bowl (Figure 3.6).

The diaphragm attaches anteriorly to the sternum, laterally to the costal cartilages and ribs seven through twelve, and posteriorly to the upper lumbar vertebrae through the pillars of the diaphragm. The pillars (or crura) are long and thick muscle bands that run vertically from the spine to the posterior of the diaphragm. Muscle fibers in the diaphragm originate from all these attachment points and insert into the central tendon, a strong, fibrous portion of the muscle that is shaped somewhat like a boomerang.

Because this muscle completely bisects the body, openings must be provided for the passage of blood and food (Figure 3.6). Fresh blood is carried to the lower body by the aorta, the largest artery in the body. The aorta passes through the diaphragm at the aortic hiatus, which is located in the center, posterior of the muscle, quite close to the spinal column. Diaphragmatic movement during respiration is minimal at this location. Oxygen-depleted blood returns from the lower body to the lungs and heart through the vena cava. This passes through the diaphragm at the foramen vena cava, which is located in the right-center portion of the central tendon (in superior aspect). The esophagus, which transports food to the stomach, passes through the diaphragm at the esophageal hiatus. It is not uncommon for people to experience problems with the esophageal hiatus, especially through a condition known as a hiatal hernia, in which the esophagus or upper stomach bulges through the hiatus to the wrong side of the diaphragm, sometimes painfully. Severe cases of hiatal hernia can be surgically corrected.

While the diaphragm is one of only two unpaired muscles in the human body, it does possess some aspects of duality. For example, it is provided with two separate blood supplies, and signals from the brain are sent to it through the two phrenic nerves. For unknown reasons, a common misconception has arisen among many singers and voice teachers that the phrenic nerve originates from the vagus nerve. Perhaps this is wishful thinking, as the nerves